

17 Lymph nodes & salivary glands

17.1 Lymphadenopathy in HIV disease

Lymph node enlargement is one of the commonest presenting signs of HIV disease; typically the nodes are small, rubbery and symmetrical in the early phases. Epitrochlear lymphadenopathy is virtually diagnostic of HIV disease. If you biopsy these nodes, the histological changes show follicular hyperplasia only. You will probably see so many patients with lymphadenopathy that you cannot reasonably biopsy them all! Also it will not be very helpful. The femoral nodes are often enlarged, especially if no shoes are worn and the feet are bare, and will not give a useful result unless obviously grossly abnormal. Look if the nodes are matted together, firm or hard, asymmetrical, and >2cm diameter; then the diagnostic yield will be significantly greater.

The main causes will be:

- (1) tuberculosis;
- (2) Kaposi sarcoma;
- (3) lymphoma; and
- (4) in Latin America, *histoplasmosis*;
- (5) in South America, *leishmaniasis* or *paracoccidiomycosis (blastomycosis)*;
- (6) in East Asia, *penicillium marneffeii* infection.

Cystic degeneration occurs particularly in the parotid and submandibular regions, and so it becomes very difficult to differentiate lymph node pathology from salivary gland disease; the two are often anyway mixed. When cysts become large, unsightly and painful, you can aspirate them: usually you find a straw-coloured fluid. Excising cysts may not be easy, especially in the neck: they may be deeper than you think, and more cysts will probably appear elsewhere later! If they occur in the parotid, you may damage the facial nerve by operating.

Excision biopsy of a lymph node in the neck may not be easy, and it will be worthwhile to develop a cytology service if possible. If general cytology is not feasible, you can at least look for AAFB's.

Macroscopic examination of a lymph node is useful if no histology is available

Do not forget that not every swelling in the neck is a lymph node! It might be a branchial (congenital) cyst, neuroma, lipoma, lymphangioma, salivary gland tumour or even a large sebaceous cyst.

17.2 Fine needle aspiration (GRADE 1.1)

To obtain a cytology specimen, insert a sterile 20 or 22 gauge needle attached to a 10ml syringe into a superficial lymph node (or tumour) and withdraw the plunger sharply and so some cells into the syringe; then expel the cells onto a dry glass slide without having let go of the plunger beforehand. It is important to examine the cells immediately; diagnosis depends much on their architecture, and you have the risk of losing the specimen in transport. Dry the slide but *do not smear it because this might destroy the cells*. Fix it in methanol, or absolute ethanol, for 3mins, and stain it with Field's stain, or better, any Romanowsky blood stains, such as Leishman, Wright, or 10% Giemsa buffered in a pH6.8 solution.

In about 40% of cases, you will be able to see caseation in a tuberculous lymph node with the naked eye, and in 70% of cases by microscopy.

You may be able, by experience and reference to standard atlases, to make more sophisticated diagnoses, but it would be wise to confirm these if at all possible by histology.

The cells of Burkitt's lymphoma (17.6) are fairly uniform in size. The cytoplasm of the cells forms a thin eccentric rim around the nucleus, is basophilic, non-granular, and usually contains some small vacuoles. The nucleus is slightly indented, and has 2-5 nucleoli, evenly distributed chromatin, and occasionally mitoses. You will not see the 'starry sky' appearance, because this is a histological, not a cytological finding. In HIV-related disease, the cells are larger with plasmacytoid features.

17.3 Lymph node biopsy

You will often be able to get extremely important information from examination of lymph nodes. Significant lymphadenopathy is matted, firm or hard, >2cm in diameter and asymmetrical. If you do not get a conclusive clinically realistic answer from aspiration cytology, you should go ahead and excise a node. *You should not use a trucut biopsy needle (24-3) for a neck node.*

Most useful biopsies come from the neck or axilla; the groin often has low-grade infection and fibrosis and unless the node is obviously abnormal, it will not be worth removing. A node may feel quite superficial, but then on exploration be under important structures, so *familiarize yourself with the anatomy* of the region you are operating in, especially the nerves. (If necessary, have an anatomy book open in theatre next to you, to give you guidance!) Although you can remove a superficial lymph node in the neck quite readily under LA, it may be helpful to add pethidine or ketamine to ease the patient's discomfort. *Do not try any node excision in children or an axillary node excision under LA.*

Remember that the neck and axilla are very vascular areas with much 'clockwork', so you must be able to see what you are doing! Therefore, make sure you have a good operating light, and preferably diathermy available. If not, be certain to have sufficient haemostats, gauze and a suction that is working available.

If you cannot remove the whole lymph node, cut it clean and take a representative sample: *do not try to be heroic and excise a huge node without seeing what is underneath!* Try to handle the node as gently as possible because you distort the architecture if you are rough, and this makes histological interpretation difficult.

INDICATIONS FOR LYMPH NODE BIOPSY

- (1) Tuberculous lymphadenitis (if fine needle aspiration is uncertain & to confirm the diagnosis).
- (2) Matted, firm or hard lymphadenopathy >2cm in diameter.
- (3) Suspicion of metastatic disease with the primary tumour unknown.

METHOD FOR NECK NODE BIOPSY (GRADE 1.5)

Position the patient with the head tilted up and turned to the opposite side. Make an incision over the node in the direction of Langer's skin lines, and extend it 1cm to either side of the node. (*Do not try to remove a node through a key-hole incision*). Deepen the incision and make sure of haemostasis. Keep the wound edges apart with a self-retaining retractor. If there is now too little room to operate, your incision is too small: go back and increase its size.

If there is only fascia covering the node, incise this and carefully extract the node with scissors using the 'push and spread' technique (4-9B). If the node lies deep to other structures (muscle, artery, vein or nerve), retract these out of the way. You may need an assistant to do this. Dissect gently down to the node, dividing only what you can see. There is usually a fairly large artery feeding the node behind it, so you should push the node to one side to see this to tie it off, or diathermy it. Carefully free the node, or cut off a part clean if it is too big to remove *in toto*. Ensure there is no bleeding; if there is some oozing, close the wound with interrupted non-absorbable 3/0 sutures around a small Penrose drain (4.9).

METHOD FOR AXILLARY NODE BIOPSY (GRADE 1.5)

Position the patient with the arm flexed under the head, which is turned to the opposite side. Make a transverse incision at least 5cm long and deepen it through the axillary fascia. Keep the wound edges apart with one or two self-retaining retractors. This exposes the fat of the axilla and the tail of the breast; here are the pectoral group of nodes. There are more nodes adjacent and behind the axillary vein which is at the upper border of the axillary fat; these nodes may be lateral, central or apical and are also close to branches of the brachial plexus. So you need to operate carefully here making sure you can see properly; gently separate the node from surrounding structures and control bleeding as you go.

Once you have sampled the node, ensure there is no bleeding and close the wound as above.

METHOD FOR GROIN NODE BIOPSY (GRADE 1.5)

Make sure the patient is bathed and clean. Position him supine; if the hair is likely to be in the way, shave it but *take care not to cut the skin*. Make a 5cm incision in the groin crease or over the node, away from anywhere where the underlying pathology is infiltrating the skin *because the wound may then not heal*. Deepen the wound through the fascia. Keep the wound edges apart with self-retaining retractors. There are many superficial veins; tie these or diathermy them to keep a dry field. There are superficial nodes just below the inguinal ligament and around the long saphenous vein. If the enlarged node is one of these, gently separate it from surrounding tissues and remove it as above. If the long saphenous vein is involved or damaged, clamp it and ligate it. There are deeper nodes in the femoral canal; palpate the femoral artery and so locate the femoral vein just medial to it. The nodes are more medial still. *Do not attempt to remove one of these unless you are prepared for a block dissection (17.8)*; satisfy yourself with a biopsy of a part only. Close the wound with a drain if you have dissected deeply.

EXAMINATION OF THE NODE

A normal node has a pale colour and is uniform; you may be able to distinguish the cortex and medulla with the naked eye. It may show abnormalities nonetheless on histology and so you should not assume it to be normal; however direct examination of nodes can give valuable instant information.

Under a good light, look for caseation or tuberculomas which are present in 75% of tuberculous nodes. Caseation may occur with lymphoma, *histoplasmosis*, *blastomycosis* and tularaemia, but these are relatively uncommon, and where tuberculosis is endemic, you should start treatment whilst waiting for the histology result.

Pus within the node or showing purulent necrosis suggests TB in over 90%, especially when surrounding cellulitis is absent. You should examine the pus and a smear of the cut lymph node on a glass slide by microscopy and ZN staining for AAFB's.

If you see hypervascular nodes, especially with a purplish colour, this is likely to be Kaposi sarcoma.

DIFFICULTIES WITH LYMPH NODE BIOPSIES

If you cannot control the bleeding, *do not plunge haemostats blind deep into a cavity*. Pack the cavity and get the suction ready. Then carefully remove the pack under a good light so you can see properly, and apply a haemostat to the bleeding vessel. If the bleeding is coming from a major vein or artery, and you cannot control it, pack the wound again and press on it. Get more assistance, put up an IV infusion of saline or Ringer's lactate and anaesthetize the patient.

Open a major dissection instrument pack, preferably with vascular clamps. For an axillary biopsy, position the patient with the head tilted up and turned away from you. *When everything is ready*, extend the incision to get good exposure and slowly remove the pack using suction.

Put vascular clamps (or haemostats) on either side of the bleeding vessel, and tie them off. *Do not be tempted to use diathermy in this situation.* If all this fails, tightly pack the wound, wait 24hrs and re-explore the next day.

If the node is too big to remove safely, cut part of the node off clean and leave the remainder.

If the node is actually an abscess, clean the cavity out and pack the wound, or if it is rather large insert a Penrose drain, and close the wound with interrupted sutures. *Do not forget to take some tissue for biopsy, and a swab for culture & AAFB's.*

If the node is actually not a node but a tumour (benign or malignant), proceed as above to try to excise it if you can. If it is stuck, just take part of it for biopsy, and close the wound.

If the node is cystic, try to excise the cyst complete with its lining. If it bursts, try to remove as much of the lining as you can to prevent its recurring.

If you find malignant melanoma (34.6) in the node, take a biopsy and prepare for a block dissection within a week. Look for the primary, and make sure that is widely excised then, if necessary with skin grafting of the defect.

If the 'node' is actually an incarcerated femoral hernia, proceed to hernia repair (18.7) with bowel resection if necessary (18.8): *do not abandon the procedure!*

17.4 Tuberculous lymphadenitis

Widespread tuberculosis of the lymph nodes is not uncommon in many areas. It usually involves the nodes of the neck, or less often those of the axilla, iliac region, or groin, mainly in children and young adults, although no age is exempt. All 4 triangles of neck may contain matted masses of glands. If these are not treated, abscesses may form and discharge through the skin, to leave sinuses which may become secondarily infected. After many months, these abscesses may heal spontaneously, to cause severe fibrosis and lymphatic obstruction in the leg, arm, breast (34.12), or vulva (23.17).

Establish the diagnosis by fine needle aspiration (17.2) or lymph node biopsy (17.3).

If you have found evidence of TB, start anti-TB treatment (5.7).

Do not excise the enlarged nodes. Do not be alarmed if they enlarge temporarily during TB treatment, or rarely, after it, without microbiological relapse. This is due to hypersensitivity to tuberculo-protein. All nodes become smaller in time.

Check the Hb level and HIV status. Antiretroviral therapy usually best waits till after TB treatment is finished (5.8).

17.5 Salivary gland enlargement

A very noticeable facial feature is bilateral parotid gland enlargement; this may be endemic especially in malnourished patients with vitamin deficiency, suffering from multiple parasitic disease, but is also a common feature of HIV disease and almost diagnostic where this is common. These patients often, but not always, have other signs of HIV disease. However, as parotid enlargement occurs even when CD4 levels are normal, there may be no other overt signs of HIV infection. Initially the parotid enlargement may be unilateral, but it almost always becomes bilateral with time. The parotids may feel lumpy or cystic or both; aspiration produces a yellowish fluid, occasionally opaque. Repeat aspiration is often necessary, and superadded infection not uncommon. The parotids may become quite grossly enlarged, particularly with tuberculosis or lymphoma; fine needle aspiration is then helpful to get a diagnosis, but operative intervention is neither useful nor safe. The enlargement will recur and facial nerve palsy is a real hazard.

Bilateral parotid enlargement may be caused by:

- (1) chronic recurrent sialadenitis,
- (2) Sjögren's syndrome,
- (3) sarcoidosis,
- (4) sialectasis in Chagas disease,
- (5) swelling from excessive pipe, glass or trumpet blowing.
- (6) leukaemia.

None of these causes warrant surgical intervention.

Acute bilateral parotid enlargement is usually viral (mumps, Coxsackie or CMV) or bacterial from acute sialadenitis due to poor oral hygiene (for example in patients with head injuries in whom mouth care has been neglected, or in patients with dental caries or ill-fitting dentures).

Chronic unilateral parotid enlargement may be due to:

- (1) tuberculosis,
- (2) actinomycosis,
- (3) tumours (17.7).

The distinction may be difficult and fine needle aspiration is very helpful.

Acute unilateral parotid enlargement may be due to:

- (1) an abscess,
- (2) acute sialadenitis due to a stone in the parotid duct: this is rarer than a stone in the submandibular duct.

Submandibular gland enlargement arises for the same causes, but because the salivary secretion is more viscous than from the parotid, stones are more likely to form.

SIGNS.

Facial nerve palsy implies malignancy of the parotid (or previous surgery). Check if a parotid swelling occupies the whole gland, or only part of it. Look at the parotid duct opening (opposite the second upper molar tooth) and the submandibular duct opening (at the side of the frenulum of the tongue); look & feel for redness, pus or a stone.

If it looks like there is an obstruction, give the patient a sweet to suck and watch the gland becoming tense and painful. Probing the duct gently may produce a gush of saliva or pus!

SPECIAL TESTS.

A plain radiograph will show up a stone; you can cannulate the duct and inject contrast to get a sialogram (38.1i) to demonstrate a stricture or impalpable stone.

If you aspirate pus, drain the parotid abscess (6.10)

PAROTID SIALOLITHOTOMY (GRADE 2.2)

Removing a stone from the parotid duct may be simple, but can be complicated. Remember the facial nerve lies close to the duct, so do not pass sutures round it as you can do for the submandibular duct.

Ask the anaesthetist to pass a nasotracheal tube to keep the mouth clear; otherwise the endotracheal tube has to be strapped well out of the way on the opposite side of the mouth. Put in a pharyngeal pack with a long thread hanging out of the mouth, so it is not forgotten! Keep the mouth open with a gag and get an assistant to hold the tongue out of the way by pulling on it with a towel-clip.

Find the parotid duct opening and pass a probe along it; put a 2/0 stay suture 5mm above and below the papilla and then cut along the duct starting at the orifice till you reach the stone. Lever it out gently. If it is not palpable, insert the probe into the duct and cut down onto it. Open the duct orifice wide by suturing together the duct wall and mucosa of the mouth, and keep it like that. Then try to manipulate the stone out with your fingers, and it is more likely a stone will pass naturally.

SUBMANDIBULAR SIALOLITHOTOMY (GRADE 2.1)

Only try to remove a stone in the submandibular duct if it is easily palpable anteriorly in the mouth; otherwise it is better to remove the whole gland with the stone. Remember the stone may fall back down the duct, so pass a ligature round the duct proximal to the stone to prevent this.

Prepare the mouth as for a parotid sialolithotomy.

Put a stay suture vertically into the floor of the mouth medial to the duct opening; pass a probe through this and then cut directly onto the stone and lever it out. Leave the duct open and do not disturb the orifice so it does not become stenosed later. If the stone is right at the orifice, push it back a bit (but not too far!) and continue as before.

DIFFICULTIES WITH SIALOLITHOTOMY

If the stone disappears into the gland, perform a submandibular gland excision (17.7) but *do not try to remove the parotid*. Instead cut back on the parotid duct as far as you can, and introduce an embolectomy catheter down it and try to manipulate the stone out by distending the catheter balloon distal to the stone. If this fails or you do not have an embolectomy catheter, try to crush the stone by passing a haemostat down the opened duct and exerting pressure on the parotid gland outside the mouth.

17.6 Lymphomas

A. ENDEMIC BURKITT'S LYMPHOMA

Burkitt's lymphoma is a non-Hodgkin's lymphoma, but because it behaves differently from the other lymphomas in this group, it has to be considered separately. There are three types:

- (1) The type which is endemic in highly malarial areas, mostly in Africa, and which is associated with the Epstein-Barr virus (EBV).
- (2) The immunodeficiency-associated type, associated with HIV disease.
- (3) The rare sporadic type seen all over the world, which is not associated with EBV. This is more common in Yemen, Somalia & Ethiopia owing to frequent chewing of *Qhat*.

Burkitt's lymphoma is a high grade tumour of B lymphocytes, and is the fastest growing tumour in man: it can double in size in 24hrs. It afflicts children from 2-16 (mean age 7); is unknown under 1, and is rare >20yrs. It is the commonest children's cancer in Africa, and in some areas it is as common as all other childhood cancers combined. In endemic areas the genome of the Epstein-Barr virus is present in 100% of tumours; in Egypt this is reduced to c.75%.

It presents as:

- (1) Swelling of the mandible or maxilla (1-4 quadrants): the commonest presentation in Africa. The earliest sign is loosening, or displacement, of a child's molar, or premolar teeth.
- (2) Proptosis, which may be marked, but is usually not painful.
- (3) Intra-abdominal tumours, especially of the retroperitoneal lymph nodes or ovaries.
- (4) Extradural lesions causing spinal cord compression and paraplegia.
- (5) Enlargement of the parotid glands, breasts (usually both), testes, thyroid, and kidneys, all of which are uncommon. Lymphomatous masses can also occasionally occur in skin or bone.
- (6) Lymph node enlargement is also uncommon, except in the abdomen.
- (7) Firm, painless, non-tender swellings, sometimes of huge size, anywhere in the body (rare).

In spite of all this, the child's general health is usually remarkably good. When the bone is involved, radiographs show osteolytic lesions.

Burkitt's tumour is a malignancy that can be cured by chemotherapy alone. Even involvement of the central nervous system is compatible with long survival. It responds so dramatically, that it should have the highest priority for chemotherapy: the prognosis is inversely proportional to the volume of the tumour, hence the importance of:

- (1) **Early urgent treatment.** If you can treat before the central nervous system is involved, there is about a 50% chance of surviving 4 more years, and probably long-term.

(2) **Tumour debulking.** If presentation is late, try, if possible, to remove the large bulk of the tumour surgically first. If you can remove more than 90% of it, you will double the survival time. Unfortunately, you are unlikely to be able to do this, except perhaps by removing a girl's ovary, or her breasts, or a mass in the mesentery. If you try, spilling the tumour is unimportant, because there will be a malignant ascites anyway. So, if a child is to be treated early, and perhaps to be treated at all, you will probably have to treat him yourself. There is no time for a leisurely workup: try to start treatment in 24-48hrs.

There are two important complications:

(1) The acute tumour lysis syndrome is a combination of lactic acidosis, hyperkalaemia, and hyperuricaemia, and is the result of the rapid destruction of a large mass of tumour. Resection of most of the tumour before chemotherapy reduces this risk. This syndrome, and the post-surgical complications of far advanced disease, are the common causes of an early death.

(2) The excretion of cyclophosphamide in the urine can cause a haemorrhagic cystitis. You can reduce both these dangers by maintaining a high urine output and by alkalizing the urine with bicarbonate.

BURKITT'S LYMPHOMA

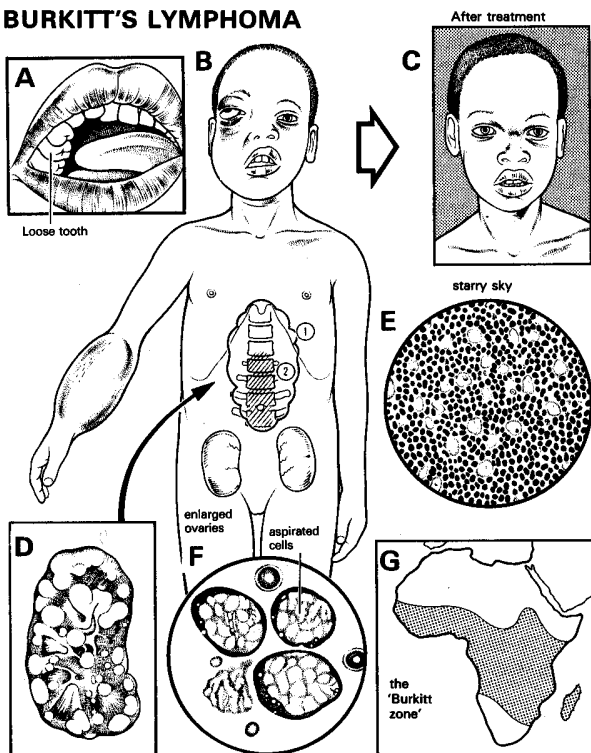


Fig. 17-1 BURKITT'S LYMPHOMA.

A, a child's first complaint may be a loose tooth or displaced teeth, and the first radiological sign, an erosion of the compact bone lining the alveolus, the lamina dura of a tooth. B, child with Burkitt's lymphoma, showing proptosis and swelling of both the upper and lower jaw on the right side. C, prompt chemotherapy is effective in >50% of cases. D, massive involvement of a kidney. E, characteristic 'starry sky' histology of Burkitt's lymphoma. F, if you aspirate a tumour and stain the cells with a Romanowsky stain, you may see cells like this. G, the 'Burkitt zone' in Africa, which is coincident with that of holoendemic or hyperendemic malaria. (1) mass of retroperitoneal lymph nodes. (2) spinal mass causing paraplegia.

DIAGNOSIS. The fact that you are in an endemic area, the child's age, and the site of a rapidly growing tumour should alert you to the diagnosis. Get radiographs. Carry out a fine-needle aspiration for cytology (17.2). Take a standard biopsy, or a smear biopsy. If possible, send a bone marrow smear for histology, and examine the CSF for malignant cells. Check the HIV status.

DIFFERENTIAL DIAGNOSIS: this varies with the site.

A swelling of the jaws: an infected tooth socket (6.9), perhaps with osteomyelitis, injury, maxillary sinusitis (29.8), a dentigerous cyst or an adamantinoma (31.6), or a nasopharyngeal carcinoma (29.16).

Burkitt's lymphoma usually displaces the teeth.

Proptosis: retinoblastoma (28.16) affects the eye itself whereas Burkitt's lymphoma usually displaces the orbit.

An abdominal swelling: tuberculous lymph nodes (17.4), other lymphomas, a nephroblastoma (27.35).

STAGING. Prognosis is directly related to stage:

Stage A Single site (often the jaw).

Stage B Two sites excluding abdomen, thorax, CNS or bone marrow.

Stage C Abdomen or thorax tumour, excluding CNS or bone marrow.

Stage D Involving CNS and/or bone marrow.

PROGNOSIS. Both cyclophosphamide alone, and the 3-drug regime described below, give a complete response rate of 95%. Cyclophosphamide alone gives a relapse rate of 50 to 60% (*but only 10% in stage A disease*); the 3-drug regime reduces this to 30%. These figures are for all stages combined. Stages A and B have a better prognosis. Relapse in HIV disease is almost certain; ARV treatment (5.8) is necessary after the chemotherapy course is completed.

If there is no relapse within 6 months of starting treatment, there is a >90% chance of a complete cure. Relapse after 1yr is unlikely, if there is complete response to the initial treatment.

CHEMOTHERAPY FOR BURKITT'S LYMPHOMA

If you cannot obtain very rapid histological or cytological confirmation, and the clinical presentation is typical, start treatment without them: the tumour may grow dramatically in a few days. *Do not delay!* Prepare for chemotherapy (37.4).

If there is a large intra-abdominal mass, or an accessible mass elsewhere, try to resect it urgently. If this is impractical, start chemotherapy alone. *Do not delay chemotherapy if early resection is impossible.*

Triple therapy reduces the relapse rate at all stages, especially in less favourable cases (stage D), or when there is meningeal involvement, or in stage C when there is a very large tumour. Stop treatment at the end of the course: maintenance therapy is of no value. *If you only have cyclophosphamide, it is still very worthwhile as a single-agent therapy.*

CYCLOPHOSPHAMIDE. Use cyclophosphamide 1g/m² IV stat, and repeat this every 2-3wks for at least 2 courses beyond complete clinical remission.

TRIPLE THERAPY. Use cyclophosphamide 1g/m² IV on day 1 plus vincristine 1.4mg/m² on day 1 and oral or IV methotrexate 15 mg/m² on day 1. Repeat these drugs every 2-3wks for one course beyond complete clinical remission.

CAUTION!

(1) Beware of the acute tumour lysis syndrome, especially if there is a large tumour burden because it may be fatal. During the first 24-48hrs maintain a high urine output, and alkalize the urine with sodium bicarbonate (the adult dose is 3g in water every 2hrs until the urinary pH>7, followed by 5-10g od).

(2) If the mass is large treat with allopurinol 20mg/kg od. As always, explain to the parents what has happened and what you are going to do. Tell them the prognosis, and that if the tumour does return, you may be able to treat him, but that follow-up is essential. Try to review monthly for the 1st year for signs of CNS relapse, presenting especially as cranial nerve palsies, drowsiness and headache.

PROGNOSIS WITH BURKITT'S LYMPHOMA

If there is no response to the initial treatment, death is inevitable in a few months, whatever you do.

If the airway, the ureters, or the gut are obstructed, the obstruction may respond to chemotherapy. So add supportive treatment (intubation, nephrostomy, nasogastric drainage) and *do not give up!*

If there is no relapse during a year after triple therapy, there is about a 90% chance of surviving indefinitely. About a 1/3 of all children have no relapses for at least 2yrs, and should survive indefinitely. The prognosis with cyclophosphamide alone is less favourable.

If there is a CNS relapse, check the HIV status again and repeat the course of chemotherapy and use weekly doses of intrathecal methotrexate (see below) until the CSF is clear of lymphoma cells.

If there is an 'early relapse' within the first 3 months of treatment, it is usually in the same site. This is common with HIV disease and abdominal tumours, and is probably a regrowth of the original tumour. The results of repeating chemotherapy are likely to be poor. Use doxorubicin 60-75mg/m² IV over 30mins every 3wks)

If there is a 'late relapse' more than 3 months after treatment, the tumour is likely to arise in a previously uninvolved site, and will probably respond rapidly to the same agent(s) used initially. A few patients have multiple successfully treated relapses, at intervals which may be as long as 10yrs.

CAUTION! *Do not neglect the opportunity of saving patients in relapse.* Follow them up carefully, and treat late relapses (>3months) aggressively, if necessary several times: vigorous treatment in relapse can nearly double the chances of survival.

DIFFICULTIES WITH BURKITT'S LYMPHOMA

If there are cranial nerve palsies (often multiple) or meningeal involvement, the central nervous system is involved. This becomes increasingly common as the number of relapses increase. Add 10mg methotrexate diluted in 10ml saline intrathecally with each course of chemotherapy.

If there is paraplegia, treat as generally described. If you can start treatment in the first 3-4days, the chances of recovery are good. If you can organize laminectomy, *i.e.* decompressing the spinal cord, do so urgently; the less the delay, the better the prognosis.

B. HODGKIN'S LYMPHOMA

This disease of the reticulo-endothelial system occurs all over the world, and is unusual in having a bimodal age distribution curve, with a peak in teenagers, and another >50yrs.

THE AGE-INCIDENCE OF HODGKIN'S DISEASE

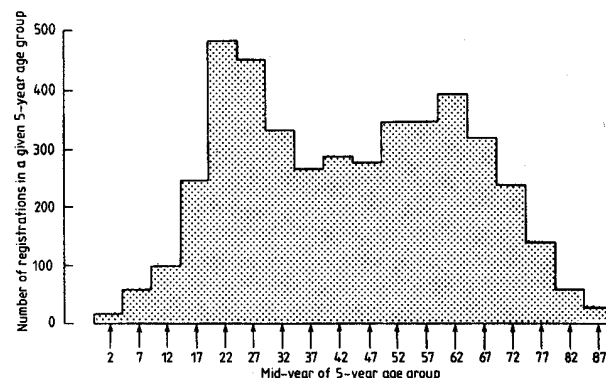


Fig. 17-2 AGE DISTRIBUTION OF HODGKIN'S LYMPHOMA - bimodal with 2 peaks. After Mould R. *Cancer Statistics*. Adam Hilger, 1983 with kind permission.

Presentation is with:

- (1) Enlarged, discrete, painless, rubbery lymph nodes in the neck (60%), mediastinum (15%), abdomen or groin (15%), or axilla, (10%).
- (2) Weight loss.
- (3) Fever which may simulate infection and is classically (but rarely) cyclical (Pel-Ebstein type) for up to 7days, followed by a remission of up to 7days.

The various histological types each have their own prognosis:

- (1) Predominantly lymphocytic (15% of cases).
- (2) Nodular sclerotic (50%).
- (3) Mixed cellularity (20%).
- (4) Lymphocyte-depleted (15%).

The nodular sclerotic type predominates <30yrs; in older patients the lymphocytic and mixed cellularity types are more common. Characteristic atypical mononuclear (Reed-Sternberg) cells must be visible to make the diagnosis.

Initially, only the lymph nodes are involved. Later, the disease spreads to the spleen, marrow, and liver.

Late complications include: obstruction to the trachea and bronchi, pleural effusion, biliary obstruction causing jaundice, cord compression, lytic and/or sclerotic bone deposits, anaemia, and infections, especially in debilitated patients.

Untreated cases deteriorate, many only slowly, and die in a few months to a few years. Radiotherapy and chemotherapy cure some of them, and cause many long-term remissions. Chemotherapy is so successful in early cases that only Burkitt's lymphoma should have greater priority.

DIAGNOSIS.

Examine all accessible lymph nodes. Note the nature and size of all enlarged ones. Feel for enlargement of the patient's liver and spleen; assess the weight loss.

SPECIAL TESTS.

Do a total and differential white count, and count the platelets. Get a chest radiograph: look for widening of the mediastinum and enlargement of the hilar lymph nodes. You must establish the diagnosis by biopsy (cytology alone cannot give you a definitive answer). Measure the blood urea. Check the HIV status.

DIFFERENTIAL DIAGNOSIS includes the common causes of lymph node enlargement (17.1).

Suggesting Hodgkin's lymphoma: painless, non-tender, rubbery discrete nodes with a uniform light greyish-yellow 'fish-flesh' cross-section.

Suggesting tuberculosis: enlarged nodes which are matted together, and occasionally tender; caseous areas on cross section.

STAGING AND RESPONSE. Here is the method of staging and the response rate (as measured by the failure of the disease to progress), that you can expect with radiotherapy, or the 'MOPP' cytotoxic régime described below, which are about equally effective. The 5yr survival rate also depends on the histological grading, and for all stages together on 'MOPP', it is 95% for 'lymphocyte predominant', 75% for 'nodular sclerotic', 55% for 'mixed cellularity', and 35% for 'lymphocyte depleted'.

SURVIVAL		5yrs	10yrs
Stage I	Single group of nodes	90%	90%
Stage II	≥2 groups of nodes same side of diaphragm.	80%	75%
Stage III	Nodes both sides of diaphragm.	60%	50%
Stage IV	Disseminated disease	45%	10%

Arranging RADIOTHERAPY will probably be impossible, so you will have to rely on chemotherapy. If you can provide radiotherapy, here are the relative indications for it:

- Stages I-II. Comparable results to chemotherapy, but radiotherapy has fewer side-effects.
- Stage III. Radiotherapy difficult because a wide area has to be irradiated; chemotherapy better.
- Stage IV. Radiotherapy impractical, chemotherapy necessary.

PREPARATION.

Prepare for chemotherapy (37.4). Sadly this is too costly in most instances; the régime mostly used is a variation of the 'MOPP' combination:

'MOPP' VARIATION: AN ESTABLISHED COMBINED DRUG REGIME FOR HODGKIN'S LYMPHOMA

Chlorambucil 6 mg/m², max dose 10mg, PO days 1-14.
(cyclophosphamide 1g/m² may replace chlorambucil)
Vincristine 1.4mg/m², max dose 2mg, IV days 1&8.
Procarbazine 100mg/m², max dose 200mg, PO days 1-14.
Prednisolone 40mg/m², PO days 1-14.

USING THE DRUGS.

Add sedation with 25-75mg chlorpromazine orally. Then use chlorambucil PO and vincristine IV 2hrs later. Use a freshly made preparation in a free running IV drip.

CAUTION! A leak will cause a severe local skin or subcutaneous tissue reaction, so infuse it with the greatest possible care.

Repeat the course monthly. Complete 6 courses, and then review monthly. Measure the total and differential white count, the Hb and the platelets weekly. Assess the response on the Karnofsky scale (37.4) and by measuring the nodes and spleen with a tape measure.

If the white count falls <2500/μl, use ½ the dose of chlorambucil and procarbazine.

SINGLE DRUG REGIMES. If you do not have the drugs for 'MOPP', treat with cyclophosphamide 1.5g/m² IV, repeated every 3-4wks, for 6 doses. Or chlorambucil, or vincristine or procarbazine, in the same doses as in 'MOPP'. These single drugs have about a 40-50% response rate, which is not as good as 'MOPP', but is much better than nothing.

DIFFICULTIES WITH 'MOPP'

If, as is more than likely, there are toxic effects, anticipate and manage them like this:

Nausea and vomiting from chlorambucil and procarbazine seldom last for >8hrs. Minimize them by adding chlorpromazine beforehand. They may limit the dose of procarbazine you can use, but tolerance increases with repeated doses.

Leucopenia from chlorambucil and procarbazine; the latter may also cause anaemia and thrombocytopenia, which may present late. Delay the drugs till the counts recover.

Local irritation, ulceration and peripheral neuritis occur if the drug leaks from a vein. They will not be helped by delaying the drugs; they take far too long to recover. Thrombophlebitis is also common. Change the veins used, and use a wide bore vessel.

Peripheral neuritis, from vincristine and procarbazine, presents as pain, weakness, loss of sensation, and hot palms and soles of the feet. These effects are usually reversible if the drug is stopped, but take time. In the next course, use only ½ the dose. Or, if pain is a problem, stop them at least temporarily. Stop them if there is any objective muscle weakness on dorsiflexion of the foot. Unfortunately, the response rate will then be much lower.

Ileus from Vincristine. Delay the next dose until the condition improves, and use ½ the dose on restarting.

Stomatitis and diarrhoea from procarbazine (unusual). Use ½ the dose.

Lethargy, hyperexcitability, and fits (uncommon) from procarbazine. Stop the drug.

N.B. The steroidal side-effects of prednisolone: raised blood pressure, moon face, increased weight, peptic ulceration, the unmasking of diabetes, etc. are seldom sufficient to stop the drug, or to reduce the dose.

If there is a relapse, the possibilities are:

- (1) Radiotherapy.
- (2) A second course of 'MOPP' with a response rate of about 50%.
- (3) An alternative regime: adriamycin 25mg/m² IV day 1&15, bleomycin 10 U/m² IV day 1&15, Vinblastine 6mg/m² IV day 1&15, dacarbazine 375mg/m² IV day 1&15 monthly for 6 courses.

C. NON-HODGKIN'S LYMPHOMA

This mixed group of lymphomas is difficult to differentiate histologically. For the purposes of prognosis they are conveniently divided into: (a) Low grade (small cell lymphocytic and follicular). (b) Intermediate or high grade (diffuse, large cell with small cell).

B-cell lymphomas are found in HIV disease.

Non-Hodgkin's lymphoma may present as:

- (1) An enlarged group or groups of lymph nodes.
- (2) Symptoms caused by enlarged nodes compressing a patient's trachea and/or the bronchi, the biliary tract, the bowel, the urinary system, or the spinal cord.
- (3) Invasion of these structures.
- (4) Involvement of the central nervous system.
- (5) Fever; this is unusual and mild.
- (6) Abdominal pain, diarrhoea and weight loss in primary gastro-intestinal tract disease.

Diagnosis, special tests and differential diagnosis are as for Hodgkin's disease

STAGING is the same as for Hodgkin's lymphoma, but is less important because 90% of patients present in Stages III or IV. The prognosis depends more on the histological type, than on the clinical stage.

PROGNOSIS. 'Small cell', high, or intermediate grade lymphomas are more likely to respond favourably. 'Large cell' tumours are likely to be unfavourable. Nodular involvement promises a better prognosis than diffuse involvement, which is, unfortunately most commonly found in children.

Untreated, low grade cases survive 7-8yrs and intermediate or high grade cases 2-3yrs, but of course this is much less if there is HIV disease also. All patients with HIV will relapse after chemotherapy unless anti-retroviral treatment is also used (5.8). This may then become complicated because of drug interactions and blood count toxicity.

INDICATIONS. Chemotherapy is the mainstay of treatment, and radiotherapy is no better.

Combination treatment: low grade follicular lymphoma, or lymphoma of intermediate or high grade type, large cell or small cell.

Single-agent treatment: low grade lymphocytic lymphoma with masses of tumour tissue, anaemia, and leucopenia.

No treatment: Asymptomatic low grade lymphocytic lymphoma, in stages 3 or 4.

PREPARATION. Establish a baseline (37.4). If necessary, transfuse blood before starting.

'CHOP': A WELL ESTABLISHED REGIME FOR NON-HODGKIN'S LYMPHOMA

Cyclophosphamide 750mg/m² IV on day 1
 Doxorubicin 50mg/m² IV on day 1
 Vincristine 1.4mg/m² (max. 2mg) IV on day 1
 Prednisolone 50mg/m² orally on day 1-5
 (Use these drugs monthly for 6 courses.)

17.7 Salivary gland tumours

About 85% of salivary gland tumours occur in the parotid gland (17-3A,B), 10% in the submandibular gland, and 5% in the mucous secreting glands inside the mouth, especially on the palate (31-16C). Similar tumours occasionally arise from the lacrimal gland (28.10, 11).

Malignant tumours need radical excision, but this is only really justified for advanced, but mobile tumours of the parotid. Even after this, some recur locally.

Malignant submandibular tumours may need a block dissection of the neck for any hope of cure. However, spread to the lymphatics and bloodstream is usually late.

There are several histological varieties.

The relatively benign ones are:

- (1) pleomorphic adenomas,
- (2) monomorphic adenomas,
- (3) adenolymphomas (usually cystic).

The more malignant ones are:

- (4) adenocarcinoma (including cylindroma),
- (5) muco-epidermoid carcinoma,
- (6) pleomorphic adenocarcinoma, and
- (7) squamous cell carcinoma.
- (8) lymphoma (17.6) can occur within the salivary gland.

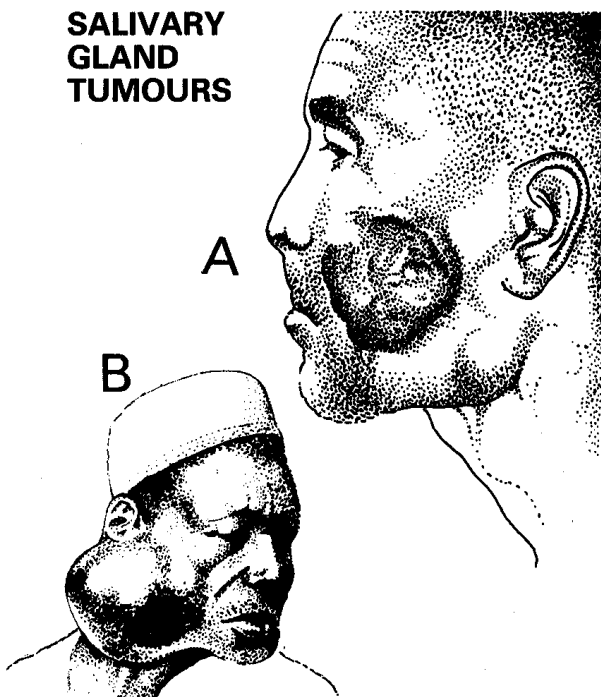


Fig. 17-3 SALIVARY GLAND TUMOURS.

A, inoperable adenoid cystic carcinoma of the left parotid, with extensive ulceration and metastases in the patient's cervical nodes. **B**, large pleomorphic adenoma, which has grown slowly over 20 yrs. After Adekeye EO, Robertson JM. *Salivary gland tumours in Northern Nigeria. Tropical Doctor* 1979;9(4):168-74 with kind permission..

The patient presents with a slowly growing mass in one of the salivary glands, which may be inside the mouth.

If there is any sign of a facial palsy, the facial nerve is involved, and the tumour is malignant. Unfortunately, the absence of a facial palsy does not mean that the tumour is benign. Even then many salivary tumours extend outside their 'capsule' and need excision with a wide margin.

DIFFERENTIAL DIAGNOSIS includes:

- (1) Lymphadenopathy (17.1), especially tuberculosis and actinomycosis
- (2) Non-salivary tumours (neuroma, lipoma, lymphangioma) and mandibular or dental tumours.
- (3) Chronic sialadenitis or sialectasia.
- (4) Masseteric hypertrophy or tumour.
- (5) Mastoiditis.

CAUTION! Do not biopsy the growth. This may spread a benign pleomorphic adenoma locally, and you may damage the facial nerve.

MANAGEMENT.

In a parotid tumour, facial palsy is the critical sign because it means the prognosis is poor, even after radical surgery and radiotherapy.

If there is no facial palsy, excise the tumour completely, and *do not merely shell it out*. This makes sure that the commonest lesion (a pleomorphic adenoma) is completely removed, and will not recur. The patient needs a conservative parotidectomy, in which the 5 branches of the facial nerve are dissected out, and the part of the gland containing the growth is removed; either its superficial part, its deep part, or both. This operation is difficult but important, because correct surgery will cure a pleomorphic adenoma, if it is early.

For a submandibular tumour, complete excision of the gland is not so difficult.

SUBMANDIBULAR SIALADENECTOMY (GRADE 2.5)

Excision of the submandibular gland is indicated for benign tumours or a retained deep stone.

Remember the mandibular branch of the facial nerve lies superficial, and the lingual nerve lies deep, to the deep part of the gland. You should discuss with your patient possible damage to these nerves and whether their sacrifice is justified in trying to remove the tumour. The 2 parts of the gland are separated anteriorly by the *mylohyoid* muscle.

POSITION

Position the patient with the head tilted up and turned away from you, stabilized on a head ring.

INCISION

Cut 5cm below the border of the mandible, parallel to it so that it extends 2cm either side of the gland, through *platysma* down to the gland (17-4A). If the tumour is here, *do not dissect right onto it*, but at a little distance from its edge. Free the superficial part of the gland by dividing the facial artery and vein above and below it.

SUBMANDIBULAR SIALADENECTOMY

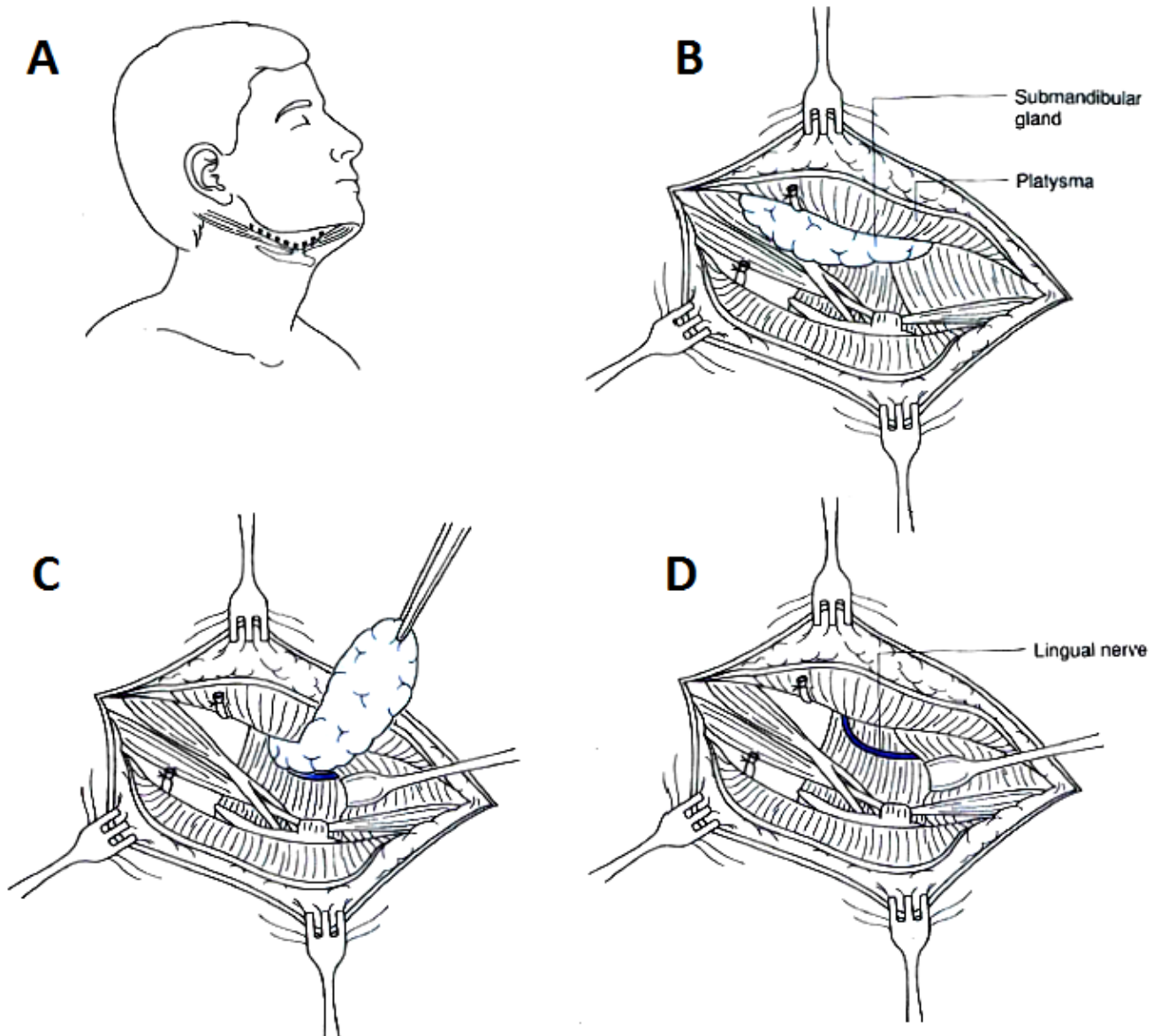


Fig 17-4 SUBMANDIBULAR SIALADENECTOMY.

A, skin crease incision. B, divide the *platysma* and retract the submandibular ramus upwards. C, lift up the gland to reveal the lingual nerve underneath. D, the view with the submandibular gland excised. After Greenfield LJ et al, *Surgery, Scientific Principles & Practice*, Lippincott-Rowen, 2nd ed. 1997 p.648.

Make sure your haemostasis is perfect. Get your assistant to retract the superficial tissues (and with it the mandibular branch of the facial nerve unless this is involved by tumour) and so completely free the superficial part of the gland.

Then, get your assistant to retract the border of the *mylohyoid* medially and pull on the gland laterally (17-4B), so you can free the deep part of the gland. *Do not hold the gland with clamps*: you may cause spillage of cells which produce a recurrence.

You can sacrifice parts of adjacent structures but *take care not to injure the lingual nerve* which is in contact with and behind the deep part of the gland, (17-4C). It runs along *hyoglossus*, and crosses the much thicker submandibular duct posteriorly. You may have to cut some branches of the lingual nerve, but try to preserve the main part of the nerve, especially when you find a stone in the duct here. Then lift out the whole gland *en bloc* and make sure there is good haemostasis once you return the patient's head to the level.

Close the wound with interrupted non-absorbable sutures around a Penrose drain.

17.8 Block dissection of the inguinal lymph nodes (GRADE 3.2)

Block dissection of the nodes of the neck or axilla (24.5) is necessary in certain cases of contained malignancy, but these are difficult operations. However, the situation in the groin is different.

Squamous cell carcinomas of the skin of the leg, and the penis, and melanoma metastasize to the nodes of the groin. Removing these metastases in a block of tissue, containing the horizontal and vertical inguinal nodes, can be very successful, because these carcinomas may be slow growing.

The femoral vein, artery, and nerves lie close to the nodes that need to be removed, and may be displaced by them. Removing them without damaging these structures is a difficult, delicate, major operation. Afterwards, there is always a lymphatic discharge and so the wound can readily become secondarily infected. Healing may be delayed, the flaps may necrose, and lymphoedema may develop in the legs (5-10%).

If you have to remove the inguinal nodes yourself, study the anatomy thoroughly before you start, and dissect carefully. Blood loss is usually not great, *provided you do not damage major vessels!*

The idea is to remove all the nodes *en bloc*, preferably without even seeing the nodes themselves; an adequate tumour clearance is essential for successful oncological surgery.

Do not try to remove nodes prophylactically, in the hope of removing metastases which you cannot feel. It will not improve the prognosis, and may be complicated by lymphoedema (34.12). Only perform a block dissection therapeutically, when the lymph nodes are palpably enlarged by secondary growth. If infection is likely to be the cause of the enlargement, confirm it by fine needle aspiration (17.2) and wait for it to improve after the amputation, and review regularly. Perform a block dissection if the nodes start enlarging. Make the decision to operate clinically, and *do not let a cytology (or biopsy) report adversely influence you*; a malignant deposit in a node may have been missed, or it may only be in other nodes, which weren't biopsied.

INDICATIONS.

(1) Clinical involvement of the inguinal nodes, with secondary deposits from squamous cell carcinoma of the penis, or leg. If a patient's nodes have not ulcerated, removing them may provide a cure. If they have ulcerated, you may be unable to remove the mass of ulcerated tissue completely. The determining factor is whether or not they have stuck to deeper structures, especially the femoral vessels.

(2) Malignant melanoma; block dissection is often only palliative, but is not always so. The nodes may be large and ulcerate.

Do not wait for this to happen before you operate, because then the nodes may be impossible to remove. The prognosis is much worse than with squamous carcinoma, because there may already be secondary deposits elsewhere.

If you need also to perform an amputation, e.g. below the knee for a squamous carcinoma, perform both operations at the same time unless the primary tumour is ulcerated and infected. If you are also going to amputate the penis, make the incisions in continuity, and perform a bilateral dissection.

METHOD.

Cross-match 2 units of blood.

Position the patient supine with a sandbag under the buttock of the affected side. Make a vertical or 'lazy S' incision (17-5A, B): this allows you to remove skin, and produces the least skin necrosis, but finding your way may be more difficult.

If some skin is involved by tumour, keep away from the diseased area, and cut an ellipse round it, so that you can excise it with the lesion.

Make the central limb 8-10cm long, centred just distal to the mid-inguinal point, where you can feel the femoral pulse. Reflect the superior flap with about 0.5cm of subcutaneous fat, and undermine it c.5cm above your incision and expose a triangular block of tissue laterally, medially, and distally. Make its apex at least 4cm distal to any palpable node. Use a knife or scissors to dissect upwards under it, until it is about 5cm wide.

At the upper extremity of the flap divide the subcutaneous tissues covering the abdominal muscles in the depth of the wound. Reflect a block of subcutaneous tissue downwards (17-5C), until you reach the inguinal ligament. *Do not cut the cord.* Clamp, divide, and tie the vessels as you go.

Divide the *fascia lata* over the lateral edge of *sartorius* and free its attachment. Try to save the lateral cutaneous nerve of the thigh going through it.

Cut through the subcutaneous tissues at the edges of the triangular mass, down to the deep fascia or muscle (17-5D). As you do so, find and clamp the saphenous vein at the lower end of your dissection. Tie it with 0 silk. Its surface marking is a line from just medial to the mid-inguinal point to the medial aspect of the medial condyle of the femur.

Avoid the femoral vessels, which lie 2-3cm lateral to the saphenous vein near the distal end of the incision. Dissect down with scissors, looking for the vessels, which are covered by a sheath. The femoral vein lies posteromedial to the femoral artery, and is largely covered by it at this point, and by the strap-like *sartorius* muscle. Tie and divide any smaller vessels you meet.

Dissect the block of tissue proximally from the apex of the wound. As you do so, remove it from the femoral vessels, for about 3cm. Retract it with tissue forceps.

Reflect medial and lateral flaps, in the same way as the superior one, as far out as you can retract them comfortably. Then clear the block of tissue from the underlying muscles. On the lateral side, you will meet the femoral nerve proximally. Continuing to work from distal to proximal, reflect the block of tissue from the femoral vessels medially (17-5E). Tie and divide any small vessels you meet, close to the main ones.

CAUTION!

(1) Pulling on the block of tissue may pull up the femoral vessels, so you may think that the femoral vein is the saphenous vein. *Do not clamp, divide, or damage the femoral vein*, which may become flat and empty as you pull on the tissues.

(2) *Try not to damage the profunda femoris or circumflex vessels* (medial and lateral), which pass deep to the muscles of the thigh.

Continue to dissect proximally. This is the difficult part. Find where the saphenous vein (which may be flat and empty) joins the femoral vein. About 1cm distal to the junction it receives several tributaries: the superficial circumflex iliac, the superficial epigastric, and the superficial external pudendal veins. When you are sure you have found it, use an aneurysm needle to pass two 0 silk ligatures under it, at least 5mm apart (17-5F). Divide it between these ligatures, *away from the femoral vein!*

The block of tissue will now be almost clear, with nothing important attached to it. Dissect it free.

If you can, try to dissect out Cloquet's node carefully in the femoral ring, and remove it. Then divide the *sartorius* muscle just below its origin on the anterior superior iliac spine, and re-position it medially to cover the exposed femoral vessels; this is readily possible. *Do not leave the vessels exposed*, or they may ulcerate and bleed disastrously. Suture the *sartorius* to the fascia of the external oblique just proximal to the inguinal ligament.

BLOCK DISSECTION OF THE INGUINAL NODES

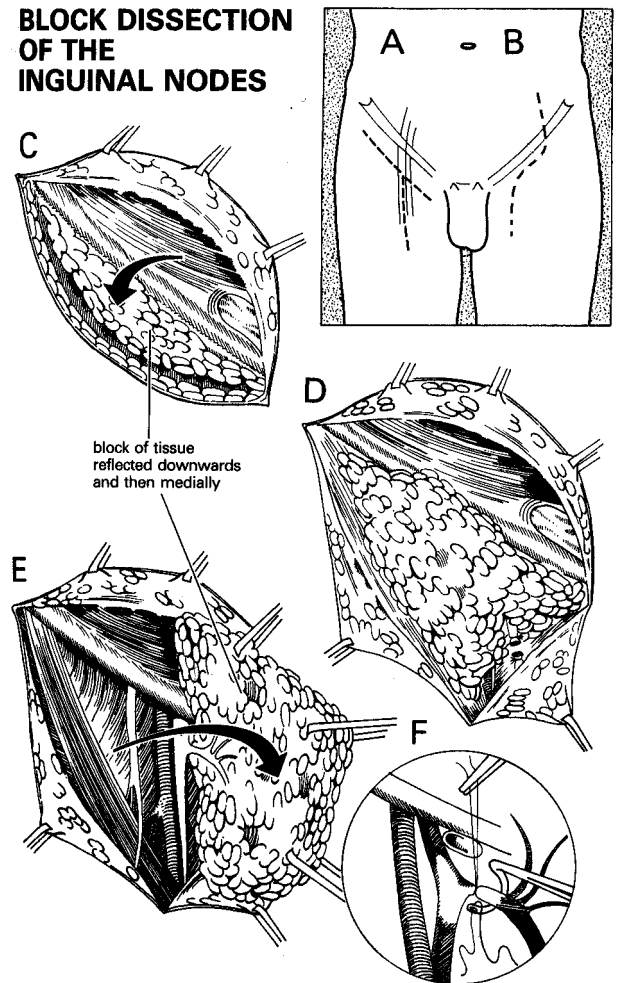


Fig. 17-5 BLOCK DISSECTION OF THE INGUINAL LYMPH NODES. A, vertical or 'T' incision. B, 'lazy S' incision. C, reflect superior and inferior flaps. D, prepare to reflect a triangular block of tissue. E, reflect a block of tissue medially from the femoral vessels. F, tie the saphenous vein.

If you can obtain good skin closure, and the wound is airtight, insert a suction drain (if you have one), with its limbs medially and laterally. If you do not have a suction drain, or the wound is not airtight, insert Penrose drains through 1.5cm incisions medially and laterally.

Beware that you do not close the wound under tension, and compress the femoral vein!

Close the skin flaps with 2/0 interrupted monofilament sutures. Apply a cotton wool pressure dressing for 48-72hrs. Remove drains when drainage has ceased. Remove alternate sutures on the 12th day, and the others when the wound seems sound.

Remember, if you are operating for carcinoma of the penis, do the same thing on the other side.

DIFFICULTIES WITH BLOCK DISSECTION OF THE INGUINAL NODES

Infection and necrosis of the skin edges are common. Complete healing takes time, but will occur.

If you injure a femoral vessel, usually the vein, press it to control bleeding, get help and prepare the instruments you need (3.1,2). Clamp the vessel above and below with artery forceps covered with suitable pieces of rubber catheter to avoid further injury to the vessels, or better, use Bulldog clamps. If possible, close the hole carefully with non-absorbable sutures, then remove the clamps.

If you cannot repair a vein and so control venous bleeding, tie the vein above and below the wound. The leg will swell, but will usually improve in time. It is rare for it to become gangrenous and be lost.

If the tumour is too big or too fixed, *do not attempt heroic surgery which may cause catastrophic haemorrhage* and result in a gangrenous leg; the tumour is anyway too advanced for surgical cure.

If you spill tumour cells from one or more nodes, there will almost certainly be a recurrence of tumour. You can reduce this risk slightly by generously washing the operative field immediately with diluted hydrogen peroxide and betadine.

If closure of the wound is difficult, *do not close it under tension*. If there is suitable muscle in the bare area, apply a split skin graft immediately and suture it in place. Or, take a graft now, store it wrapped in paraffin gauze in sterile saline, and apply it 5days later. If the femoral vessels are exposed, mobilize the *sartorius*, as described above. Or use a *gracilis* flap.

If lymphoedema develops, advise raising the leg at night, and prop it up when sitting. If possible apply a graduated compression elastic bandage, or as a poor second best, a crêpe bandage.